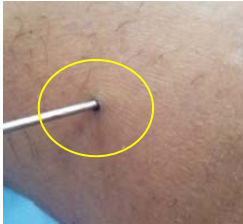


DIFFERENT OF WOUND APPEARANCES & THEIR GRADING

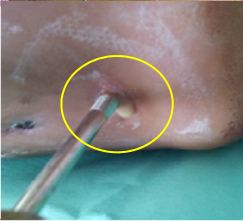
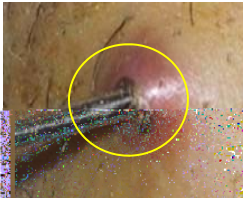
GRADE 0: HEALTHY WOUND

Dry or wet wound with clear /
whitish discharge .



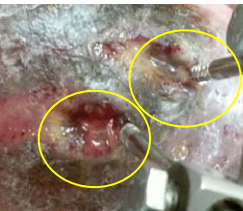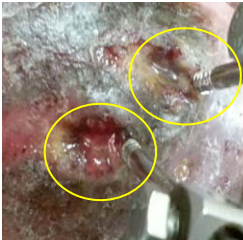GRADE 1: MILD INFECTION

Surrounding tissue becomes red/
inflamed **or** presence of cloudy
yellowish pus / discharge.



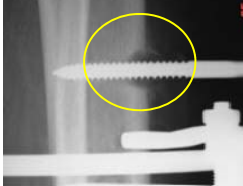
GRADE 2: MODERATE INFECTION

Surrounding tissue becomes red
or inflamed **and** presence of
cloudy yellowish pus /
discharge.



GRADE 3: SEVERE INFECTION

Grade 2 findings with
radiological evidence of
osteomyelitis .



WHEN YOU SHOULD SEE THE DOCTOR?

1. Unexplained high fever
2. Evidence of grade 2 or grade 3 infection
3. Deterioration in range of motion
4. Excessive pain , redness and swelling
5. Recent onset of numbness or weakness
6. Loosening of external fixator frame
7. Correction seems to have stopped or progressing towards the wrong direction

Disediakan Oleh

Ismahani Binti Saidin

Jururawat Gred U29 (Wad 9U Otopedik)

Tel : 012-9030495

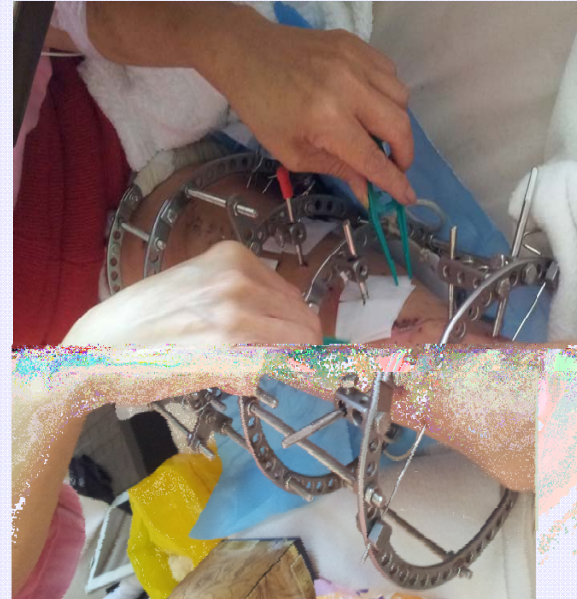Sebarang Pertanyaan Sila Hubungi

Perkembangan Kejururawatan, Tingkat 8, Menara Utama

Pusat Perubatan Universiti Malaya, 59100 Kuala Lumpur

Tel : 03-79492376/ 2931/ 2798/ 2412

Hak milik Pusat Perubatan Universiti Malaya 2013



PIN SITE CARE (HOME DRESSING PROTOCOL)

HOME DRESSING PROTOCOL



1. Washing your hand with soap & water.



2. Lay out the dressing set & prepare normal saline.



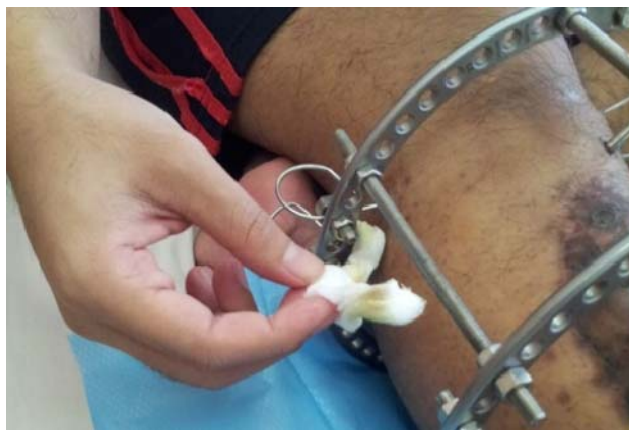3. Cut dressing gauze into small pieces (OPTIONAL)



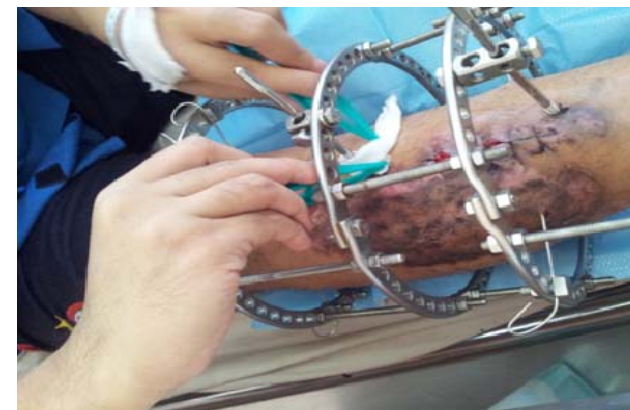
4. Prepare PHMB gauze— Polythexamethylene Biguanide (OPTIONAL).



5. Prepare wet saline gauze.



6. Remove old dressing with fingers.



7. Apply new dressing with forceps.



8. Clean dressing set with soap & water.



Disinfect set once a week using boiling water.